

Influence of an artificial cervical joint compared with fusion on adjacent-level motion in the treatment of degenerative cervical disc disease

CRISPIN WIGFIELD, F.R.C.S., STEVEN GILL, F.R.C.S., RICHARD NELSON, F.R.C.S.,
ILANA LANGDON, F.R.C.S., NEWTON METCALF, B.Sc., AND JAMES ROBERTSON, M.D.

*Departments of Neurosurgery and Orthopaedic Surgery, Spinal Research Unit,
Frenchay Hospital, Bristol, United Kingdom*

Object. The authors report the preservation of motion at surgically treated and adjacent spinal segments after placing an artificial cervical joint (ACJ) and they describe the influence of interbody fusion on changes in angulation occurring in the sagittal plane at adjacent levels in the treatment of cervical spondylosis.

Methods. The authors conducted a prospective nonrandomized study of patients in whom an ACJ was placed or autologous bone graft interbody fusion was performed. Angular measurements at levels adjacent to that surgically treated were calculated using plain flexion–extension radiographs obtained at 6-month intervals. Analyses of qualitative data, such as increase or decrease in adjacent-level motion, and the degree of disc degeneration were performed. Quantitative data were also analyzed. In the fusion group a significant increase in adjacent-level movement was demonstrated at the 12-month follow-up visit compared with the group of patients in whom ACJs were placed ($p < 0.001$). The increase in movement occurred predominantly at intervertebral discs that were preoperatively regarded as normal ($p < 0.02$). An overall reduction in adjacent-level movement was observed in patients who underwent joint replacement, although this was compensated for by the movement provided by the ACJ itself.

Conclusions. Fusion results in increased motion at adjacent levels. The increase in adjacent-level motion derives from those discs that appear radiologically normal prior to surgery. It remains unknown whether ACJs have a protective influence on adjacent intervertebral discs.

KEY WORDS • artificial joint • cervical spondylosis • spinal fusion

ANTERIOR cervical decompression and fusion were first described by Smith and Robinson²¹ and by Cloward⁴ in the late 1950s. Although the procedure has become popular with spine surgeons, recently, as with procedures involving lumbar vertebral fusions, concerns have been expressed that interbody vertebral fusion may result in an acceleration of adjacent-level disease. Evidence of this comes from clinical experience, radiological studies, and biomechanical and mathematical models.^{7,13,17,22} Some patients subsequently undergo sequential intervertebral fusions (Fig. 1).

Fusion alters the normal biomechanics of the spine. The consequent reoperation rate for adjacent-level disease is 2.9% per year,¹⁰ and at 10 years following the initial operation, 25% of patients exhibit symptoms of the adjacent-level disease.⁹ Preserving the range of spinal motion rather than fusing the degenerating spine may limit the segmental progression of disease that affects some patients. Attempts at creating an artificial intervertebral disc have met with limited success.^{2,5,11} In most clinical experiences

involving such implants, surgeons have treated patients with lumbar disease (Rapp S, unpublished data). In the late 1980s Cummins, et al.,⁵ tried to maintain motion in the cervical spine by using a simple ball and socket-type joint. Their technique was problematic, but in the majority of cases cervical vertebral motion was preserved. The authors concluded that further investigation into artificial joints was warranted.⁵ The NFCJ was developed. It is a semirestrained, two-component joint that allows movement in both rotation and translation in three planes. The goal is that this joint can replace the intervertebral disc at one or more levels in the cervical spine. Its design permits a variable axis of rotation and translation that mimics human vertebral movement in the middle to lower cervical spine. Biomechanically the kinematics of the NFCJ closely reproduce normal cervical motion (DiAngelo, et al., unpublished data).

In the United Kingdom a prospective pilot study of the ACJ was conducted involving 15 end-stage patients in whom previous fusion had been performed or adjacent disc disease was present. Patients suitable for receiving an ACJ were those most at risk of developing adjacent-level disease were a standard fusion procedure to be performed. The indications for cervical joint replacement included

Abbreviations used in this paper: ACJ = artificial cervical joint; MR = magnetic resonance; NDI = Neck Disability Index; NFCJ = New Frenchay Cervical Joint.

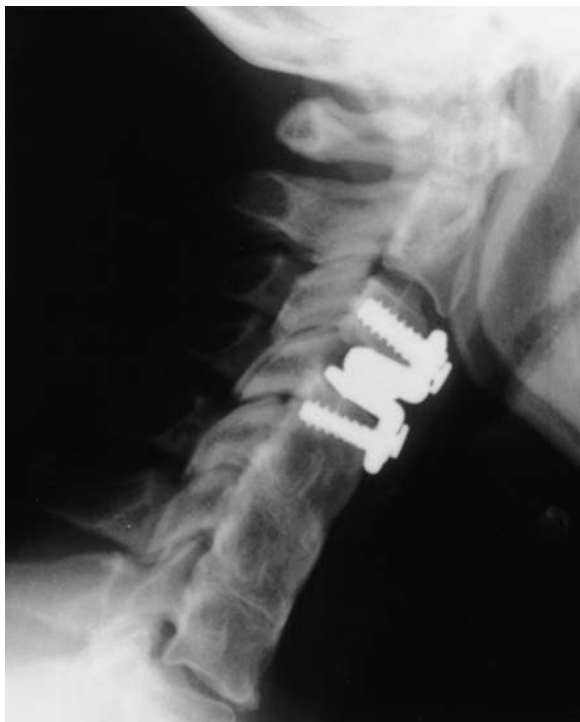

FIG. 1. Representative radiograph of a cervical spine obtained in a patient in whom an ACJ was placed at C3–4 after having previously undergone multiple cervical interbody fusions.

presentation with radiculopathy and/or myelopathy with radiological evidence (computerized tomography or MR imaging) of compression by osteophyte or herniated disc material, in the presence of an adjacent surgically created or congenital cervical fusion. An alternative entry category was for patients with evidence of asymptomatic disc degeneration, adjacent to the symptomatic disc targeted for surgery, even if there had been no previous fusion.

Simultaneously a prospective observational study was conducted of patients in whom standard single-level autologous bone graft fusion for degenerative cervical spine disease was a primary intervention.

Using data prospectively obtained from both these studies, we investigated the influence of an ACJ on adjacent level vertebral motion.

Clinical Material and Methods

A prospective nonrandomized study of patients managed with an ACJ or single-level autologous bone graft fusion was conducted with the aim of investigating two issues (Table 1). First we endeavored to assess changes in vertebral angulation demonstrated on flexion and extension radiographs acquired in the sagittal plane and, secondly, to determine if the preoperative condition of the adjacent intervertebral discs was associated with any observed changes in angular displacement. We started with a null hypothesis: “there is no difference in adjacent-level motion in the spines of patients undergoing fusion compared with those receiving an ACJ.” Radiological evidence of complete fusion at the operative level (no move-

TABLE 1

Inclusion criteria

joint replacement or single-level fusion
surgery between January & December 1998
minimum of 1 year follow up
high-quality radiographs & MR images w/ good visualization of adjacent segments
fusion confirmed at 6 months on flexion–extension radiographs obtained in patients receiving autograft

ment on flexion–extension x-ray films) by 6 months was required in patients in the fusion arm of the study.

Twelve patients in whom an ACJ replacement and 13 patients in whom a single-level autologous fusion had been performed were identified as having complete sets of plain cervical radiographs and MR images of sufficient quality to assess adjacent-level motion and the degree of disc degeneration. Angular measurements were taken using an Oxford Cobbometer²⁴ and rounded to the nearest degree. The discs adjacent to the level undergoing surgery were classified as either “normal” or “deteriorated” according to the absence or presence of osteophytes and loss of disc height demonstrated on preoperative plain radiographs or evidence of disc bulging visualized on preoperative sagittal and axial MR images. Both quantitative and qualitative data were analyzed. Because of the diverse patient groups and small numbers in each arm of the study a combination of nonparametric, chi-square, and Fisher exact tests were used to analyze the data.

From the radiographs we calculated the angular displacement of the adjacent vertebrae preoperatively and at 6 months and 12 months postoperatively. The reference points for acquiring angular measurements were the vertebral endplate lines or the spinous processes. Motion at the ACJ was measured from the implant–endplate interface for both components. The NDI scores were compared between the two groups of patients at the same time intervals (Table 2).

Radiographs and MR images were independently assessed, and the measurements, obtained by two observers, were subjected to a paired t-test. There were no significant differences between the observers’ measurements. The data were grouped by any change in angular displacement (either an increase or decrease of $\geq 1^\circ$) and also by the normal or deteriorated condition of the discs. Statistical analysis of subgroup data were performed using the Fisher exact test.

Results

Demographic Variables

There were no significant differences between the two

TABLE 2

Mean NDI scores for both groups of patients

Time Interval	ACJ Group (range)	Fusion Group (range)
preop	42.3 (2–74)	32.7 (0–86)
6 mos	33.5 (2–70)	23.2 (0–64)
12 mos	33.5 (2–74)	23.8 (0–74)

Artificial cervical joint for adjacent-level motion

TABLE 3
Demographic data obtained in both treatment groups

Characteristic	No. of Patients	
	ACJ Group	Fusion Patients
no. of patients	12	13
age in years (range)	49 (31–74)	57.8 (27–85)
sex		
male	9	10
female	3	3
smoker	5	5
involved in litigation	2	0
receiving Workers' Compensation	0	0

groups in terms of age, sex, smoking status, litigation, or Workers' Compensation status (Table 3).

Preservation of Motion

In all cases the joint demonstrated angular motion between flexion and extension. This ranged from 2 to 13° with a mean of 7.1° of motion at 12 months (Table 4). Translation in an anteroposterior direction of 2 mm was achieved, although this was more apparent in cases in which ACJ was placed in the upper cervical spine.

Adjacent-Level Motion

Preoperatively there was no significant intergroup difference in the adjacent-level movement. By 12 months postoperatively, however, a significant difference had developed (Mann–Whitney U-test, $p = 0.011$).

In the fusion group there was a significant increase in adjacent-level movement at follow up (range 2–17°; mean 9°) compared with an overall reduction in adjacent-level movement in patients who had received an ACJ (Fig. 2) ($p < 0.001$). In patients who had undergone fusion, adjacent-level motion increased from preoperative levels by 5% at 6 months to 15% at 12 months (Fig. 3). At all stages in the assessments, proportionately more movement was observed at the upper cervical levels than the lower ones. A cumulative increase of 20° was achieved at upper levels compared with 10° at lower levels by 12 months in the fusion group (Fig. 4).

There was a highly significant difference ($p < 0.001$) demonstrated for increased adjacent motion in the fusion group compared with decreased adjacent motion in the ACJ group (Table 5). Subgroup analysis in which the Fisher exact test was used showed that increased motion occurred at normal discs but not at deteriorated discs ($p < 0.02$) (Table 5).

An overall slight reduction was observed in the angular displacement at adjacent levels in patients in whom the ACJ was implanted, although movement provided by the joint itself compensated for this. Motion provided by the joint was similar to motion demonstrated preoperatively at the level undergoing surgery (Table 4).

Comparison of the NDI scores, determined at 12 months postoperatively using a two-tailed paired t-test, showed a significant improvement in the ACJ group ($p < 0.002$). A similar trend in improvement was seen in the fusion group ($p = 0.052$). As anticipated, because the ini-

TABLE 4
Motion occurring at the level at which the ACJ was placed

Time Interval	Mean Measurement (°)
preop	6.6
6 mos	7.2
12 mos	7.1

tial NDI scores were higher in the group receiving the ACJs, we are cautious about interpreting this finding (Table 2).

Discussion

There is considerable controversy regarding the optimum treatment: spinal fusion or preservation of intersegmental motion. Robinson and Smith¹⁸ noted that undesirable osteophytes located at the level of the fusion spontaneously regress once a stable fusion has been achieved, and this has been interpreted as a desirable event. Others have clearly seen an acceleration of degenerative change in the discs and vertebrae adjacent to a fusion mass both in the lumbar and cervical regions.^{1,3,9,10,12} There is, however, no clear correlation between changes seen radiographically and the clinical condition of patients.⁸

Increasing attention is being paid to the incidence of adjacent-level disease following successful fusion. In our department a retrospective study of patients who underwent anterior cervical decompression and fusion revealed a subsequent adjacent-level operation rate of 2% per year (Grundy & Nelson, unpublished data). Hilibrand and colleagues^{9,10} reported a similar rate of 2.9% per year and subsequently demonstrated that at 10 years post-fusion, up to 25% of patients were symptomatic from adjacent level disease. Does fusion or preservation of motion influence the natural history of degenerative cervical disease?

Examination of retrospective data derived from procedures performed via the posterior approach to remove lateral soft-disc herniation provides some clues. In using this approach segmental motion is preserved and the reopera-

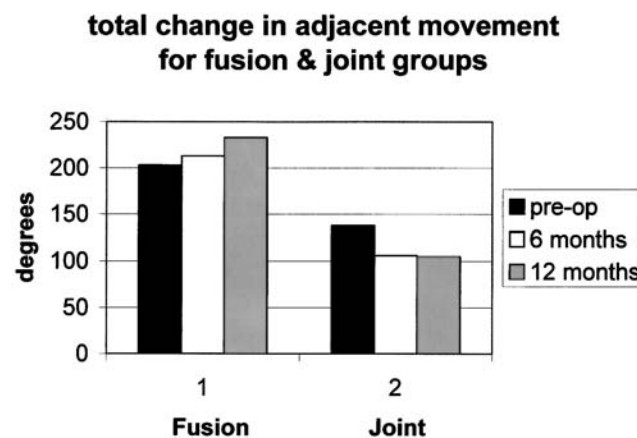


FIG. 2. Bar graph showing total cumulative change in adjacent-level movement for both groups preoperatively and at 6 and 12 months postoperatively.

% change in adjacent level movement for fusion & joint groups

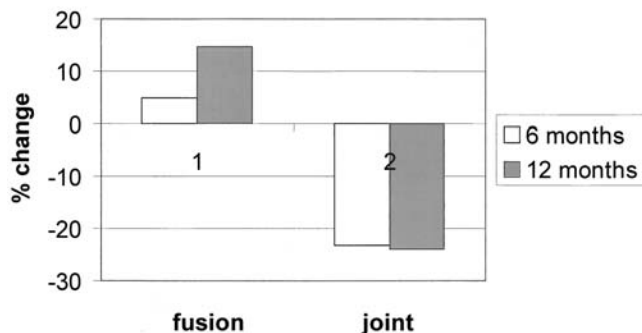


FIG. 3. Graph showing the mean percentage change in adjacent-level movement at 6 months and 12 months postoperatively.

tion rate is approximately 1%.^{14,15,19} The anterior approach is, however, favored in the cervical spine because it provides good access to the majority of the symptom-inducing disease. Subsequent fusion reduces spinal mobility, and the adjacent-level operation rate is increased three-fold. Motion at the ACJ was approximately half of that normally reported for cervical vertebral motion according to several authors.^{6,16,23} In their studies measurements were obtained in healthy, young, asymptomatic volunteers. In our study there was on average a half-degree difference between the preoperative motion at the level undergoing surgery and the postoperative motion provided by the ACJ. We believe that preexisting degenerative changes in the facet joints and neighboring spinal ligaments determine the range of movement of the NFCJ. Thus the range of motion is physiologically appropriate to each individual patient.

We believe that in patients in whom the ACJ is implanted because of previous fusions increased adjacent-level movement may already have been established, and what we observed could have been a gradual reversal of this process. An alternative explanation is that the patients in the ACJ group were younger than those in the fusion group and that the latter represented a cohort with unusually advanced degenerative spine disease. This theory is supported by the NDI scores obtained in the patients in the ACJ group, which were higher than those in the fusion group. The natural history of advanced disease in these patients may be progression of degeneration at several levels simultaneous with an associated loss of motion at all motion segments. If this should prove to be the case, then the ACJ in this study simply acted as a spacer that preserved motion at the operative level but will possibly not influence the natural history of cervical spondylosis at other levels. We do not know what effect the ACJ-related range of motion has on the facet joints, but we have not observed any changes at the facet joints.

Our observations do not clarify whether increased movement at adjacent levels is disadvantageous; however, Shea, et al.,²⁰ have demonstrated that cervical discs are more prone to failure in the lower cervical spine where motion is greatest.

We suggest that these results are of interest, although

TABLE 5

Number of patients in both groups with increased motion, increased motion at deteriorated discs, and increased motion at normal discs 12 months postoperatively

Increased Motion	ACJ Group	Fusion Group	Total No.
overall*			
yes	1	9	10
no	11	4	15
total no. of patients	12	13	25
at deteriorated discs†			
yes	2	6	8
no	5	5	10
total	7	11	18
at normal discs‡			
yes	1	12	13
no	6	3	9
total	7	15	22

* chi-square test = 12.35 (p < 0.001).

† p = 0.225 (Fisher exact test).

‡ p = 0.02 (Fisher exact test).

not conclusive, regarding the role of ACJs and their effect on adjacent levels. To determine if a clinical advantage can be gained using an ACJ a prospective randomized trial is required. Long-term follow-up studies will be required to determine if changes in adjacent-level movement can influence the natural history of the disease in a clinically significant way.

Conclusions

This is the first study to show that intervertebral disc replacement may have an influence on adjacent vertebral levels and that it may maintain motion at the site that would otherwise be subjected to fusion. Additionally, using the NDI score we have demonstrated that an operation to relieve pain and preserve motion in the neck can significantly improve a patient's disability postoperatively.

The main role for ACJs remains to be clarified. They could be reserved for use in patients with advanced disease and previous fusions, with the primary goal of preserving motion at the operative site. Alternatively, there may eventually be a convincing argument to introduce

change of angle in degrees at 12 months

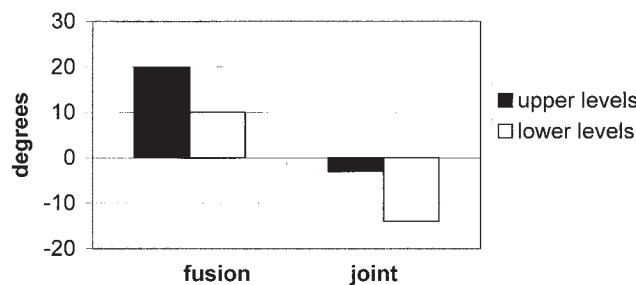


FIG. 4. Graph showing cumulative changes in motion in which proportionately greater movement occurred at upper cervical levels in both groups.

Artificial cervical joint for adjacent-level motion

ACJ therapy, the goal of which would be to prevent progression of cervical spondylosis. Additional studies with large patient populations may resolve these issues.

Acknowledgments

The authors thank Marlene Soden, Superintendent Radiographer, and Helen Bromwich, Deputy Superintendent Radiographer, who performed all radiographic studies at Frenchay Hospital in Bristol.

References

1. Aota Y, Kumano K, Hirabayashi S: Postfusion instability at the adjacent segments after rigid pedicle screw fixation for degenerative lumbar spinal disorders. **J Spinal Disord** **8**:464–473, 1995
2. Bao QB, McCullen GM, Higham PA, et al: The artificial disc: theory, design and materials. **Biomaterials** **17**:1157–1167, 1996
3. Cherubino P, Benazzo F, Borromeo U, et al: Degenerative arthritis of the adjacent spinal joints following anterior cervical fusion: clinico-radiologic and statistical correlations. **Ital J Orthop Traumatol** **16**:533–543, 1990
4. Cloward RB: The anterior approach for removal of ruptured cervical disks. **J Neurosurg** **10**:602–617, 1958
5. Cummins BH, Robertson JT, Gill SS: Surgical experience with an implanted artificial cervical joint. **J Neurosurg** **88**:943–948, 1998
6. Dvorak J, Panjabi M, Novotny J, et al: In vivo flexion/extension of the normal cervical spine. **J Orthop Res** **9**:828–834, 1991
7. Gore DR, Sepic SB: Anterior cervical fusion for degenerated or protruded discs. A review of one hundred forty-six patients. **Spine** **9**:667–671, 1984
8. Gore DR, Sepic SB, Gardner GM: Roentgenographic findings of the cervical spine in asymptomatic people. **Spine** **11**:521–524, 1986
9. Hilibrand AS, Carlson GD, Palumbo M, et al: Radiculopathy and myelopathy at segments adjacent to the site of a previous anterior cervical arthrodesis. **J Bone Joint Surg (Am)** **81**:519–528, 1999
10. Hilibrand AS, Yoo JU, Carlson GD, et al: The success of anterior cervical arthrodesis adjacent to a previous fusion. **Spine** **22**:1574–1579, 1997
11. Kostuik J: Intervertebral disc replacement. Experimental study. **Clin Orthop** **337**:27–41, 1997
12. Lee CK: Accelerated degeneration of the segment adjacent to a lumbar fusion. **Spine** **13**:375–377, 1988
13. Matsunaga S, Kabayama S, Yamamoto T, et al: Strain on intervertebral discs after anterior cervical decompression and fusion. **Spine** **24**:670–675, 1999
14. Murphey F, Simmons J, Brunson B: Surgical treatment of laterally ruptured cervical disc. Review of 648 cases, 1939–1972. **J Neurosurg** **38**:679–683, 1973
15. Odom G, Finney W, Woodhall B: Cervical disc lesions. **JAMA** **166**:23–28, 1958
16. Penning L: Normal movements of the cervical spine. **Am J Roentgenol** **130**:317–326, 1978
17. Pospiech J, Stolke D, Wilke HJ, et al: Intradiscal pressure recordings in the cervical spine. **Neurosurgery** **44**:379–384, 1999
18. Robinson R, Smith G: Anterolateral cervical disc removal and interbody fusion for cervical disc syndrome. **Bull Johns Hopkins Hosp** **96**:223–224, 1955
19. Scoville W: Types of cervical disc lesions and their surgical approaches. **JAMA** **196**:479–481, 1966
20. Shea M, Edwards WT, White AA, et al: Variations of stiffness and strength along the human cervical spine. **J Biomech** **24**:95–107, 1991
21. Smith G, Robinson R: The treatment of certain cervical-spine disorders by anterior removal of the intervertebral disc and interbody fusion. **J Bone Joint Surg (Am)** **49**:607–622, 1958
22. Weinhoffer SL, Guyer RD, Herbert M, et al: Intradiscal pressure measurements above an instrumented fusion. **Spine** **20**:526–531, 1995
23. White AA III, Panjabi MM: **Clinical Biomechanics of the Spine, Ed 2**. Philadelphia: JB Lippincott, 1990
24. Whittle M, Evans M: Instrument for measuring the Cobb angle in scoliosis. **Lancet** **1**:414–415, 1979

Manuscript received May 18, 2000.

Accepted in final form July 12, 2001.

Address reprint requests to: Crispin Wigfield, F.R.C.S., Spinal Research and Development Unit, Room 4, The Academic Centre, Frenchay Hospital, Bristol BS16 1LE, United Kingdom. email: cagincourt@cs.com.